



Angioaccess

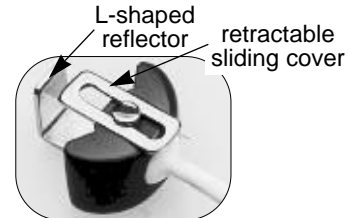
Intraoperative Blood Flow Measurement

Anders Lundell, MD, PhD, Nils H. Persson, MD, PhD,
Transplantation Unit, Dept. of Surgery, Malmö General Hospital, Malmö, Sweden

Probe Sizes:

Radial, ulnar artery: H4SB
Vein conduit: H4SB

Flowprobe with L-shaped reflector and cover which slides closed to fully enclose the vessel.



Surgical Approach:

The patency of the radial and ulnar arteries is checked by simple pulse palpation. If the pulses are not palpable, a hand-held Doppler together with a non-invasive blood pressure measurement are used to check patency. Should one of these arteries be occluded, we choose the contra-lateral arm for the A-V fistula. The radial artery is used as the inflow vessel.

Under local anesthesia, the vessel is dissected free in the fossa tabatiere, and flow is measured at the wrist using an ultrasound transit time flowmeter (*Transonic Systems HT107*). We use a 4 mm probe and fill the space with acoustic gel or physiological saline. The signal is allowed to stabilize for 15-20 seconds before flow is recorded. A flow of more than 100 ml/min is considered sufficient for a successful reconstruction. Should the radial artery flow be less than 100 ml/min, we prefer to use the brachial artery for the inflow vessel.

Venous conduit arm veins *in situ* are preferred. If no arm veins are available, a small segment of a reversed saphenous vein is used. A third choice is ePTFE. The anastomosis is done end-to-side to the artery with running ePTFE sutures (CV7 or CV8). After completion of the anastomosis, the arterial flow proximal (1) and distal (2) to the anastomosis as well as in the vein (3) are measured. (*Due to the air content in the wall, direct measurements on newly inserted ePTFE grafts are not possible.*)

A post-reconstruction flow less than the pre-construction flow could be caused by vessel spasm, a technical error, or thrombus formation. If there is a spasm tendency, 40 mg of papaverin is locally infiltrated along the artery and vein while the flow is continuously monitored by the flowmeter. If there is no apparent spasm, a thrombectomy is done through a small vein incision placed perpendicular to the longitudinal axis of the vessel. The thrombectomy is followed by an on-table angiogram through the incision. The incision is closed by single CV8 ePTFE sutures. The flow is restored and another flow measurement is made.

