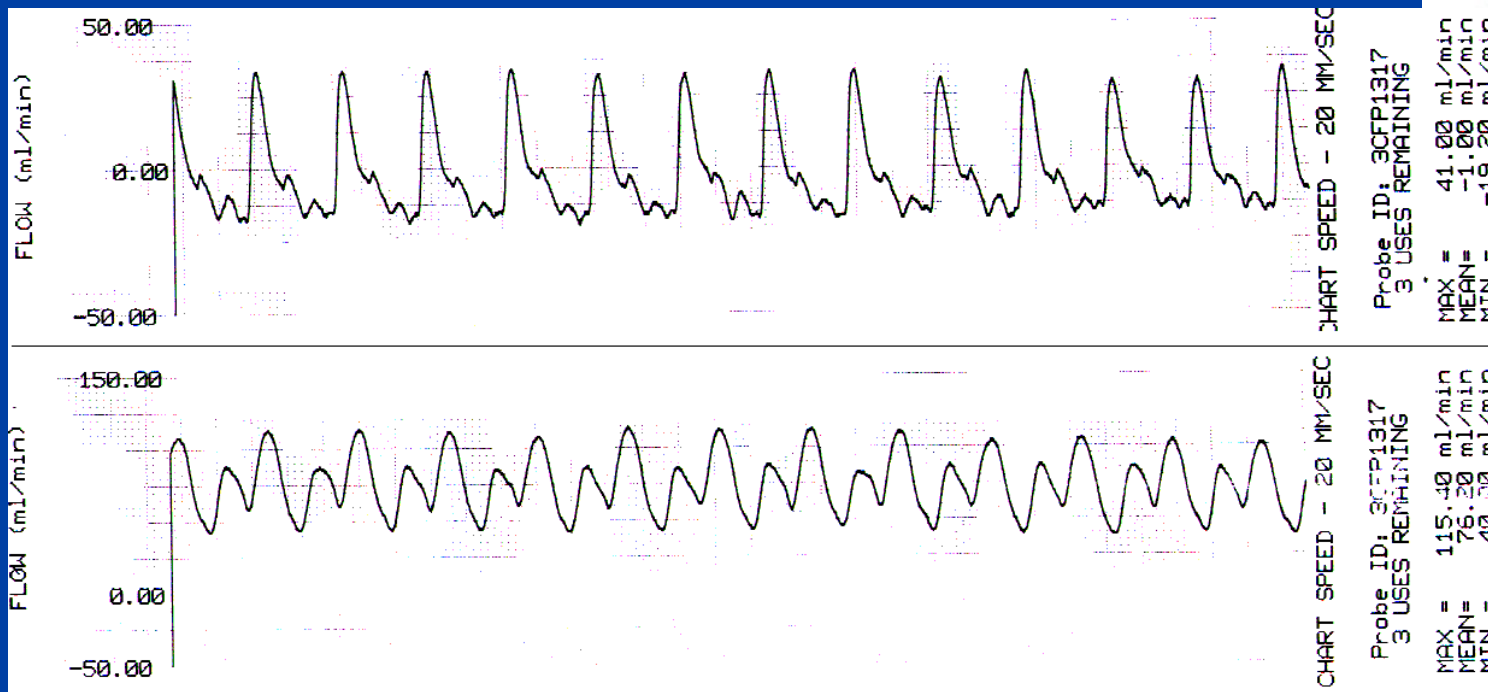
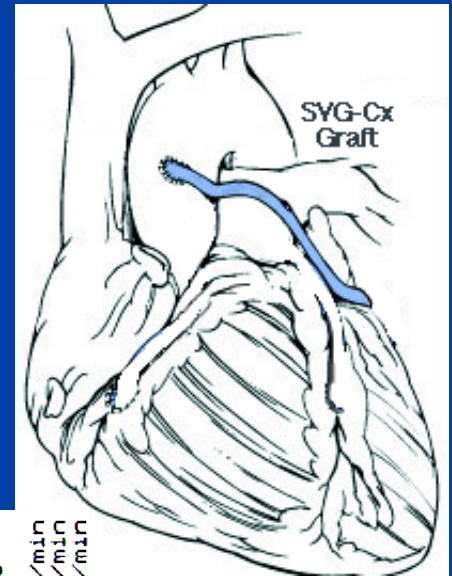


Flow-QC Case Study

10. SVG- Cx Clot Removed from Graft



An 81-year-old male OPCAB patient received a SVG-Cx graft. Initial mean flow measured zero ml/min (PI: 22). Examination of the graft disclosed a clot which was declotted via intra-aortic balloon pumping (IABP). When IABP was removed, graft flow measured 76 ml/min; PI was 2. (CABG Handbook, page 37.)